

# ViewPoint 6

GE Healthcare

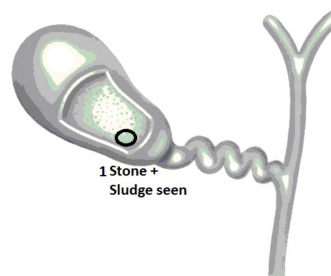
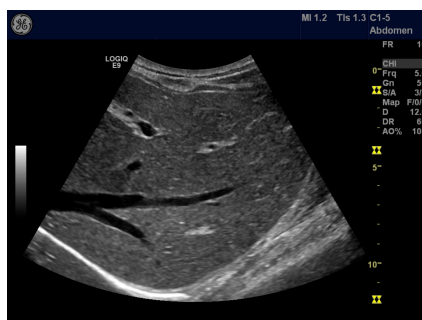


Thomas C. Abdomen  
7148 South 4th St.  
Asheville NC 28802

Date: 4/26/2010

## Abdominal Ultrasound

- Indication** Recurrent abdominal pain.
- Liver** 2 cm cyst, round, circumscribed, thin-walled, anechoic structure producing posterior enhancement Right upper lobe near diaphragm.  
Length 16.7 cm, Width 17.4 cm.
- Gallbladder** proper position, normal size, sludge , 1 cm stone detected.  
Length 5.2 cm, Thickness of gallbladder wall 1.7 mm.
- Bile Ducts** intra- and extrahepatic bile ducts not dilated, no stone detected, no intraluminal lesion detected.
- Pancreas** WNL where visualized.
- Spleen** normal size, homogeneous, no focal lesions, clear hilum.  
Length 4.3 cm, Width 2.0 cm, Height 5.5 cm, Volume 24.8 cm<sup>3</sup>.
- Right Kidney** orthotopic positon, normal size, normal shape, no urine retention detected, no stones detected.  
Length 10.0 cm, Width 6.0 cm, Height 4.0 cm, Volume 125.7 cm<sup>3</sup>.
- Left Kidney** orthotopic positon, normal size, normal shape, no urine retention detected, no stones detected.  
Length 11.3 cm, Width 7.5 cm, Height 4.2 cm, Volume 186.4 cm<sup>3</sup>.
- Bladder** normal size, wall without pathological findings, no intraluminal lesion detected.
- Abdominal Aorta** Within normal limits.
- Impression** One 2 cm simple cyst seen in the right lobe of the liver.  
One 1cm stone visualized in the gallbladder with a small amount of sludge.  
Otherwise Normal abdomen ultrasound.



B. Miller  
Sonographer

Dr. B. Winter  
Performing physician

CC: Robert Smith, New York